



Lisa Annabel Weber (Autor)

# **In vitro and in vivo development of a topical drug for the treatment of equine skin cancer - based on naturally occurring and synthetically modified substances in plane bark**

**Wissenschaftliche Reihe  
der Klinik für Pferde**

Herausgegeben von  
Karsten Feige, Peter Stadler,  
Harald Sieme, Bernhard Ohnesorge



Lisa Annabel Weber

***In vitro* and *in vivo* development of a topical drug  
for the treatment of equine skin cancer - based on  
naturally occurring and synthetically modified  
substances in plane bark**



STIFTUNG TIERÄRZTLICHE HOCHSCHULE HANNOVER

**51**



Cuvillier Verlag Göttingen  
Internationaler wissenschaftlicher Fachverlag

<https://cuvillier.de/de/shop/publications/8452>

Copyright:

Cuvillier Verlag, Inhaberin Annette Jentsch-Cuvillier, Nonnenstieg 8, 37075 Göttingen, Germany

Telefon: +49 (0)551 54724-0, E-Mail: [info@cuvillier.de](mailto:info@cuvillier.de), Website: <https://cuvillier.de>

## 1. Introduction

Skin cancer is a major area of interest within the field of equine oncology. Indeed, cutaneous neoplasms account for about 50 % of all equine neoplasms, making the skin the organ most frequently affected by tumors in horses [1,2]. Four primary skin tumors are mainly diagnosed in horses: equine sarcoid, squamous cell carcinoma, equine melanoma, and papilloma [2,3]. Skin cancer in horses can cause economic losses for the horse owner due to cosmetic issues, breeding impairment and interference with saddle gear [4,5], but it can also lead to serious illness and death of the animal [6,7]. The latter two points in particular make treatment necessary from a medical and ethical point of view. However, despite the sophistication of modern equine medicine, the treatment of skin cancer is still a challenge for the equine veterinarian. For these reasons, the current thesis contributes to the development of a novel veterinary drug for the topical treatment of equine cutaneous cancer. The main focus of the thesis is on equine melanoma, but experiments were also conducted that may benefit the development of a treatment for equine sarcoid. Natural products play an increasing role in the field of anticancer drug discovery, development, and application [8,9] and so the investigated compounds in this thesis are also either directly isolated from botanical sources or they are synthetically modified derivatives of these compounds. The research project on which the thesis is based was part of a collaboration project between the University of Veterinary Medicine Hannover (Hannover, Germany), the Martin-Luther-University Halle-Wittenberg (Halle, Germany), the University of Veterinary Medicine Vienna (Vienna, Austria), Biosolutions Halle GmbH (Halle, Germany), and Skinomics GmbH (Halle, Germany).

### 1.1. The equine malignant melanoma

Melanomas are malignant tumors of the pigment building melanocytes [10]. Melanocytes derive from neuroectodermal melanoblasts and are mainly located in the skin, especially within the *stratum basale* of the epidermis and in the outer root sheath of hair follicles [11]. In two database surveys with 236 and 964 equine neoplasms respectively, melanomas were reported to account for 4 % – 6 % of all neoplastic lesions [12,13]. However, most reports on tumor incidence and prevalence in the literature are based on histopathologic confirmation. Since biopsies are rarely used by clinicians to diagnose melanoma in horses, the true occurrence is probably much higher [2]. Although melanomas can occur in horses and mules of any hair color, they are primarily a disease in grey-coated horses. In a study with 296 grey Lipizzaner horses the prevalence of melanoma in the overall population was 50% [14]. Another survey demonstrated that 31% of 264 grey Camargue-type horses suffered from these tumors, while the incidence of melanoma was significantly correlated with age [15]. Indeed, reported prevalences of 67% – 80% in grey-coated horses older than 15 years underline the importance

of the disease especially in aging animals [14–16]. There seems to be no sex predisposition for the condition [4,17,18].

### 1.1.1. Tumor classification

Currently, a generally recognized classification system for equine melanocytic tumors of the skin is missing. Based on clinical presentation, histopathology, tendency to malignant transformation, and response to surgical excision, some authors distinguish between four manifestations [4,17,19,20]. Briefly, *melanocytic nevi (benign melanocytoma)* are benign-appearing collections of melanocytes located in the superficial dermis or dermo-epidermal junction. They predominantly occur in young horses of any coat color, mostly in sites others than those described for equine dermal melanoma. Surgical excision is generally curative. The rare *anaplastic malignant melanomas* are composed of extremely pleomorphic, occasionally amelanotic epithelioid cells and are typically encountered in aging (>20 years) non-grey and grey horses. They commonly develop lethal organ metastases. *Dermal melanomas* and *dermal melanomatosis* affect grey horses with distinct predilection sites. Both conditions show a very similar histological appearance, presenting as heavily-pigmented tumor cells in the deep dermis, and are therefore classified based on clinical features. *Dermal melanomas* occur in mature, but not aged grey horses as discrete, solitary masses that are surgically excisable. Multiple, coalescing lesions which are often found in aging grey horses are referred as *dermal melanomatosis*. They show a greater potential for metastasis.

Other authors recommend to generally address melanocytic tumors in horses as malignant neoplasms or neoplasms with malignant potential [7,21,22]. As most melanomas in grey horses undergo a transformation from benign to malignant the term "equine malignant melanoma" (EMM), as proposed by Moore and colleagues in 2013 [21], is used in the following.

### 1.1.2. Etiology

A relationship between the grey coat color and melanoma development in horses was already described at the beginning of the 20<sup>th</sup> century [16,23]. Even though the etiology of melanomas in horses is still not fully clarified, current data suggest that tumor evolution is associated secondary to genetic mutations in the melanin metabolism molecular pathway. Grey horses are born black, bay or chestnut. Due to an autosomal dominant inheritance they turn to a grey phenotype early in life and show a high incidence for vitiligo-like depigmentation and melanoma [24,25]. Compared with heterozygote horses (*G/g* genotype), homozygous horses (*G/G* genotype) show a much faster and completer greying process and suffer from greater prevalence and severity of melanomas [23]. The causative mutation for the grey phenotype is a 4.6-kb intronic duplication in the gene syntaxin 17 (*STX17*) [23,26]. Further, an overexpression

of the neighboring NR4A3 (nuclear receptor subfamily 4, group A, member 3) gene as well as a loss-of-function mutation of the agouti signaling peptide (ASIP) has been suggested to promote dermal melanocyte proliferation in glabrous skin of grey-coated horses [23].

Melanomas in humans have been strongly related with a high exposure to ultraviolet (UV) light [27]. With respect to the dark skin pigmentation, which grey horses maintain throughout their life and which provides good protection against UV light and with regard to the from UV radiation well protected predilection sites of the tumors (e.g. ventral tail, after, guttural pouch), it seems very unlikely that UV radiation has a significant role in the pathogenesis of melanoma in horses [11,28].

### *1.1.3. Gross pathology and diagnosis*

Corresponding to the age when coat-color starts to turn grey or white, the vast majority of tumors appear around the age of five years [19,21]. Early stages of the disease frequently occur as single, black-pigmented, slow-growing and mostly dermally located firm nodules. Predilection sites are glabrous skin regions like the ventral tail root, anus, perineum, external genitalia and occasionally the lips and eyelids [14,15]. Further, they are found on visceral sites in the head (guttural pouch, parotid salivary gland, larynx) [29,30]. With advanced disease multiple and rapid in volume increasing tumors can arise, which frequently present a coalesced, cobblestone-like pattern [19]. Large tumors often ulcerate through the epidermis and exhibit necrotic centers due to deficits of blood supply [18]. Approximately two-thirds of horses affected by melanoma have tumor metastases at necropsy [7,31]. Metastases to any region of the body can occur secondary either to hematogenous or lymphatic spread [7,17], but reports about primary visceral masses exist [7,32,33]. Most common sites for metastases are the regional lymph nodes, liver, lung, spleen, heart, and major blood vessels [7,34] but spinal cord [35] and muscles [7] can be affected also.

Diagnosis can be set clinically based on the typical gross characteristics and localizations of the lesions in conjunction with the horses' signalment (grey-coated). Fine-needle aspirations or biopsies for cytological and histopathological examinations confirm the clinical diagnosis. However, a histopathological determination of the malignancy potential is not always possible [4]. Immunodetection of the receptor for activated C kinase 1 (RACK1) was proposed as a potential marker for malignancy in equine melanoma cells [36].

### *1.1.4. Clinical signs in diseased horses*

Clinical signs depend on the localization of the lesions, the grade of local invasion and presence of internal metastases. Small EMM may simply be a cosmetic blemish but – if localized on the head – can also become sore and infected secondarily through contact with snaffle or bit [4]. If the anal sphincter, penis and prepuce, or vulva commissure are physically obstructed by larger

tumors, dyschezia, dysuria, and difficulty with coitus and parturition may result [4]. As for human melanoma patients, mortality in melanoma-affected horses is principally related to metastatic spread to sites distant from the primary cutaneous tumor [37]. However, defecation problems and resulting colic, caused by large cutaneous tumors in the anal area, can also require the euthanasia of the horse. Metastases of EMM have been reported to cause neurologic deficits like lameness of the pelvic limbs, ataxia, dysphagia and Horner's syndrome, but patients are also presented with unspecific signs like weight loss, colic and exercise-intolerance [7,35,38–40].

With regard to the frequently malignant development, the prognosis for horses suffering from EMM is guarded. The clinical problems often arise because of either misjudgment or incorrect management or irresponsible benign neglect of the lesions [11].

#### *1.1.5. Current treatment options*

Because of the potential to grow and progress to malignancy, even early stage EMM should be considered rather precancerous than benign – regardless of histopathological classification and slow-growing nature of the lesions [22]. Consequently, any melanoma in horses should be treated [7,11]. Although various approaches have been introduced, there exists no uniformly satisfactory therapy for the disease. Current locoregional or systemic treatment modalities include (cryo)surgery [11,41,42], cimetidine application [43,44], (electro)chemotherapy [45–47], immunotherapy [48–50] and radiation [51,52]. Nevertheless, these therapies are often inefficient, challenging, not commercially available, or lack sufficient data to be considered established. Although the surgical excision may be curative for solitary tumors [41,42], there are limits for surgical interventions when the tumors involved are already confluent or close to important anatomical structures like nerves, vessels, the anal sphincter, or major organs. The local chemotherapeutic approach with cisplatin has been reported to be effective in some lesions [45–47]. However, as a result of its indiscriminate toxicity to both normal and cancer cells the use of the mutagenic cisplatin is linked to strict safety rules [47,53] and, therefore, the therapy is not offered by many clinics.

Commercially available, validated topical (epicutaneous) treatment options for EMM are currently missing. A report exists about the topical therapy of an EMM lesion with toremifene, a triphenylethylene derivative, which resulted in slight tumor volume reduction [54]. Positive therapeutic effects were observed after topical administration of frankincense oil in five EMM affected horses as described in a PhD thesis [55]. However, results of both studies were never confirmed in further evidence-based large-scale trials.

## 1.2. The equine sarcoid: an overview

Equine sarcoids (ES) are the most common tumors in horses worldwide [56,57]. From 536 equine (muco)cutaneous neoplasms, ES were diagnosed in 51 % of cases and, therefore, exceeded the sum of all other skin cancer in horses, donkey and mules combined [3]. Skin trauma [58,59] and bovine papillomaviruses type 1 and 2 [60–62] play an important role in the etiopathogenesis, but also a genetic predisposition has been associated with the occurrence of the disease [63,64]. Sarcoids are coat-color and gender independent, semimalignant neoplasms of the cutaneous fibroblasts, capable to metastasize into the local tissue and regional lymph nodes but not into internal organs [59,65]. Based upon their morphological characteristics they can be classified in six types: mild occult or verrucous tumors and more severe nodular, fibroblastic, mixed, and malevolent lesions [59]. Predilection sites include the head, neck, extremities, and ventral abdomen, which often leads to interference with bridle and saddle girth and occasionally cause lameness [57]. Sarcoids can significantly affect the animals' welfare, function, and aesthetics due to tumor localization, size, and number. Therefore, the economic value of sarcoid-affected equids is often substantially impaired [57]. The treatment of these skin tumors can be challenging. Thus, it is not surprising that multiple therapeutic approaches have been described, which can be divided into different categories, such as surgery [66–68], chemotherapy [45,69–72], immunotherapy [73–76], radiotherapy [77–79], photodynamic therapy [80,81], phytotherapy [82,83] and others [84]. Their application depends on tumor type, size, number, duration, localization and previous treatments, experience and facilities of the individual veterinarian, compliance of owner and equine patient, and treatment costs [84]. Unfortunately, resistance to therapy or recurrence in exacerbated forms is frequently observed [6].

## 1.3. Topical drug application

### 1.3.1. *Why the topical (epicutaneous) approach to treat equine skin cancer?*

Given the size of equine patients, the logistical effort as well as the costs for diagnostic processes and treatments can be high [11]. Apart from the financial burden and risks associated with surgical removal of tumors under general anesthesia, the localization of EMM and ES can limit the possibility of surgical intervention or lead to complications in wound healing [30,84]. Furthermore, the systemic treatment of cancer-affected horses with chemotherapeutic agents is restricted mainly by high costs for materials and hospitalization but is also not optimal due to possible systemic side effects on normal cells [11].

The topical (epicutaneous) therapy of skin tumors with anticancer drugs is an interesting alternative to maximize local drug delivery into neoplastic lesions with reduced side effects to

normal tissues and simultaneously increased therapeutic benefits [85]. Topical treatments, for example in the form of an ointment or a cream, are non-invasive and can easily be applied even to unfavorable tumor localizations. Additionally, the topical approach provides a treatment opportunity associated with relatively low costs for the horse owner. After instruction by a veterinarian, the horse owner can carry out the treatment without the need for special equipment or facilities, which also significantly reduces the stress factor on the horse. The topical therapy of small EMM lesions would be a better alternative to the common practiced approach of benign neglect, which is often advocated by equine veterinarians and horse owners because of the slow-growing nature of the tumors and the lack of reliable treatment methods for this disease [7,21,22]. Although topical therapies for ES treatment are already utilized, they differ in their efficacy and for some preparations only anecdotal evidence exist [69–71,83,84,86]. Thus, an evidence-based topical therapy, which has been investigated by *in vitro* and *in vivo* experiments from the very beginning, is also needed for this form of skin cancer.

### 1.3.2. Drug transport across the skin

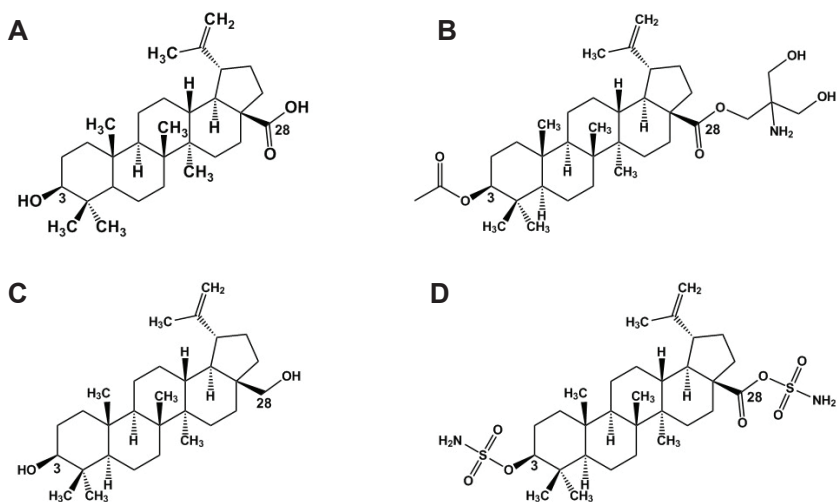
The major challenge in the development of a topical drug is to transport the anticancer substance to the tumor cells in sufficiently high quantities to kill them. Here, the major barrier to be overcome for topically applied compounds is the outermost avascular layer of the skin: the *stratum corneum*. The *stratum corneum* is composed of dense, functionally dead, and with keratin filaments aggregated corneocytes that are surrounded by a lipid matrix consisting of primarily cholesterol, cholesterol esters, fatty acids, and ceramides [85,87–89]. On the one hand, these structured lipids prevent the body from losing water [90]. On the other hand, they block entry of many topically applied drugs [90] and exogenous substances from the environment. In order to deliver an anticancer substance to a tumor localized in the superficial or deep dermis, the substance must first dissolve homogeneously in the transport vehicle (e.g. cream, ointment) [91]. After application to the skin, the compound must release from the pharmaceutical formulation and penetrate the *stratum corneum* either between the lipids of the corneocytes (intercellular route) or through the corneocytes (intracellular route) [87]. Although their contribution to drug transfer is low the skin appendages, particularly hair follicles and sweat glands, are also included in skin permeation [85,87,92]. After the lipid milieu of the *stratum corneum* is passed, the agent has to permeate the hydrophilic viable epidermis to reach the superficial and deep dermis [87,91]. However, because of vascularization of the dermis, blood vessels absorb large amounts of the substance and a subsequent systemic circulation takes place [87,91]. Several techniques exist to overcome physiological as well as tumor-induced skin barriers and to favor drug permeation into deeper skin layers. Strategies include the utilization of chemical penetration enhancers like dimethyl sulfoxide or propylene glycol, the

use of nanocarriers, such as liposomes and polymeric and lipid nanoparticles, and the application of physical penetration enhancers like iontophoresis and electroporation [85].

*In vitro* methods such as Franz-type diffusion cell (FDC) experiments with isolated skin [93] are valuable tools for the development and screening of pharmaceutical formulations as they help to predict the *in vivo* cutaneous penetration and permeation [87,94]. Due to possible interspecies differences in skin structure, it is of great advantage if skin of the target species can be used for *in vitro* experiments [95]. However, the whole complexity of biological systems including metabolism, distribution, and elimination of drugs cannot be reproduced by laboratory trials and *in vivo* data may have to follow the initial evaluations [87,94,95].

#### 1.4. Naturally occurring substances in plane bark and their synthetically modified derivatives

In previous (screening) cell culture experiments, the project partners and the author of the thesis tested naturally occurring substances in plane bark (betulin and betulinic acid) and several of their synthetically modified derivatives in EMM cells [96 and unpublished data]. Based on these experiments and existing literature listed below, it was finally decided that the following compounds would be used within the scope of the PhD project: betulinic acid, betulinic acid derivative NVX-207 and betulin derivative betulinyl-bis-sulfamate (Figure 1).



**Figure 1.** Chemical structures of (A) betulinic acid, (B) NVX-207, (C) betulin, and (D) betulinyl-bis-sulfamate.

Structural formulae drawn with ChemDraw (PerkinElmer, Waltham, MA, USA)



#### 1.4.1. Betulinic acid

Betulinic acid (BA; 3 $\beta$ -hydroxy-lup-20(29)-en-28-oic acid; molecular weight (MW): 456.7 g/mol) is a pentacyclic lupane-type triterpene [97]. Triterpene compounds commonly occur in the plant kingdom and perform a protective function against microorganisms and insects [98]. Because of their anti-inflammatory [99–101], antimicrobial [102,103], anthelmintic [104], anti-viral [105,106], and wound-healing properties [107] plants with high content of triterpenes have already been used as phytotherapy in folk medicine since centuries [108]. The compound BA is found in various botanical sources, but considerable amounts can be extracted from the bark of white birch tree species (*Betula* sp.) and plane trees (*Platanus acerifolia*) [109–111]. Furthermore, it can be obtained by chemical or enzymatic oxidation of betulin [110,112]. Since BA's selective cytotoxicity against human melanoma cells was demonstrated in 1995 by *in vitro* cell culture experiments and a murine model [113], a considerable amount of literature has been published on its *in vitro* and *in vivo* anticancer activity against various human malignancies [97,111]. Amongst these are neuroectodermal derived tumors like melanoma, medulloblastoma, glioblastoma and Ewing's sarcoma [115–117], but also ovarian, breast, lung, prostate, renal, and colon carcinoma [114,118]. Many studies reported about BA's mediation of selective cell death in tumor cells, while normal non-cancerous cells of different origin seem to be much more resistant to the compound [113,119,120]. In addition to these *in vitro* observations, the substance was well tolerated in tumor-bearing mice even at high concentrations (up to 500 mg/kg bodyweight) after oral and intraperitoneal application [113,117,121,122]. The antitumor effects of BA are mediated mainly by the activation of the mitochondrial (intrinsic) pathway of apoptosis [115,123]. Through the modulation of pro- and antiapoptotic Bcl-2 family proteins [115,116], BA increases the permeability of the outer mitochondrial membrane [124,125]. Cytochrome *c* and apoptosis-inducing factor are released into the cytosol and the subsequent cleavage of caspases leads to the fragmentation of nuclear DNA and cell shrinkage [123–125]. Additional studies with BA have shown it to induce the generation of reactive oxygen species [115,126,127] which results among others in the activation of proapoptotic mitogen-activated protein kinases [128]. BA-mediated anticancer properties are further explained by the inhibition of topoisomerase I and II [129–131] and induction of antiangiogenic effects within the tumor as a consequence of vascular endothelial growth factor and aminopeptidase N regulation [132–136]. Although extensive research has been carried out on BA's anticancer effects in cells and murine models, no published study exists which reports on the application in human tumor patients. The main disadvantage of BA seems to be its poor water solubility and pharmacokinetic parameters, which limit the use to topical application only [109,110]. Therefore, more than hundred semi-synthetic lupane analogues, derivatives of BA and betulin, were published up to today

[109,110]. For the synthesis of derivatives, modifications of BA and betulin molecules mainly concern active groups at the C-3, C-20 and/or C-28 position [98].

#### 1.4.2. *Betulinic acid derivative NVX-207*

Amongst a variety of BA derivatives, NVX-207 (3-acetyl-betulinic acid-2-amino-3-hydroxy-2-hydroxy methyl-propanoate; MW: 601.8 g/mol) has been identified as one of the most biologically active and pharmacologically significant substance [96,110,137]. Indeed, NVX-207 shows a higher cytotoxicity in various human and canine cancer cell lines compared to the parent BA [96,137,138]. Besides its more potent activity, significant advantages over BA include a better solubility in aqueous solutions and pharmaceutically suitable solvents [139]. In accordance with BA, NVX-207 was found to induce cell death in cancer cells via activation of the intrinsic apoptotic pathway by cleavage of caspases-9, -3, -7 and poly (ADP-ribose) polymerase [96,137,138], while the impact on the *in vitro* survival of normal human umbilical vein endothelial cells, fibroblasts and keratinocytes was low [137]. An accumulation of EMM cells in the subG1-phase and externalization of phosphatidylserines to the extracellular side of the plasma membrane, a characteristic feature of apoptosis, were observed after treatment with NVX-207 [96]. The compound was already successfully tested in a clinical study with five canine cancer patients suffering from squamous cell carcinoma, soft tissue sarcoma, mammary carcinoma, or adenocarcinoma and clinically beneficial tumor responses including a complete regression were observed [137]. In a pilot safety study with two EMM affected horses the repeated intralesional injection of the compound over 19 consecutive weeks was safe and well tolerated [96]. However, the application of the test substance into the firm tumor tissue required high injection pressures and proved to be difficult, which demonstrates again the advantage of a topical treatment. Summarized, the favorable chemical features of NVX-207 together with the already existing data about its anticancer properties make this substance a well-suited candidate for further preclinical and clinical investigations.

#### 1.4.3. *Betulin derivative betulinyl-bis-sulfamate*

Betulinyl-bis-sulfamate (BBS; (3 $\beta$ )-Lup-20(29)-ene-3,28-diol, 3,28-disulfamate; MW: 600.3 g/mol) is a derivative of betulin, one of the most commonly found naturally occurring triterpene [98,140]. BBS has been introduced as an efficient inhibitor of human carbonic anhydrase isoenzymes I, II and IX [140]. The cell-surface glycoprotein carbonic anhydrase IX is overexpressed in human melanoma cells and other malignancies [141,142]. It is involved in complex pathways leading to changes in tumor microenvironment (e.g. pericellular acidification) and subsequent tumor progression [141–143]. A combination of proton pump- and carbonic anhydrase IX inhibitors did lead to enhanced anticancer effects in human

melanoma cells *in vitro* [141]. Based on these data, BBS could represent a potential candidate as anti-tumor agent alone or as adjunctive therapeutic drug in skin cancer affected horses.

### 1.5. Hypotheses and aims of the thesis

The overall aim of the thesis was the development of a topical drug for the treatment of equine skin cancer, whereby the main focus of the investigations was on EMM. On the basis of literature and preliminary data, the active ingredient should be based on naturally occurring or synthetically modified substances found in the bark of plane trees. In addition, the compounds were to be tested in ES cells in order to draw conclusions regarding their effects and mechanisms of action and to enforce the generation of new hypotheses for future research projects focusing on the treatment of equine skin cancer. The thesis is organized in four manuscripts either already published in or submitted to peer-reviewed journals. The manuscripts describe *in vitro* and *in vivo* studies that build upon each other and aimed to test the central hypotheses as well as to achieve the overall goal of the thesis.

#### Hypothesis 1:

*Naturally occurring or synthetically modified substances found in the bark of plane trees have antiproliferative and cell viability reducing effects on equine melanoma cells and equine sarcoid cells in vitro. The mode of action is apoptosis.*

#### Hypothesis 2:

*Naturally occurring or synthetically modified substances found in the bark of plane trees can, when applied topically in an appropriate vehicle, penetrate and permeate horse skin in vitro and in vivo in concentrations sufficiently high enough to exert antitumoral effects against equine skin cancer cells.*

#### Hypothesis 3:

*Topically applied naturally occurring or synthetically modified substances found in the bark of plane trees have antitumoral effects on early stage EMM in vivo.*

The **objectives** of the first *in vitro* study, as described in **manuscript I**, were

- to assess the antiproliferative and cell viability reducing effects of BA on primary equine melanoma cells and primary equine dermal fibroblasts
- to demonstrate a selective cytotoxicity of BA to equine melanoma cells, and
- to investigate the penetration and permeation ability of BA in a pharmaceutical test formulation on isolated equine skin